

# Histologic evaluation and removal torque analysis of nano- and microtreated titanium implants in the dogs

Seok Ahn<sup>1</sup>, DDS,MSD, Mong-Sook Vang<sup>2</sup>, DDS, MSD, PhD, Hong-So Yang<sup>2</sup>, DDS, MSD, PhD, Sang-Won Park<sup>2</sup>, DDS, MSD, PhD, Hyun-Pil Lim<sup>3</sup>, DDS, MSD

<sup>1</sup>Graduate student, <sup>2</sup>Professor, <sup>3</sup>Clinical professor, Department of Prosthodontics, Graduate school, Chonnam National University, Gwangju, Korea

**STATEMENT OF PROBLEM.** A number of studies about the nano-treated surfaces of implants have been conducting along with micro-treated surfaces of implants. **PURPOSE.** The purpose of this study was to get information for the clinical use of nano-treated surfaces compared with micro-treated surfaces by measuring removal torque and analyzing histological characteristics after the placement of various surface-treated implants on femurs of dogs. **MATERIAL AND METHODS.** Machined surface implants were used as a control group. 4 nano-treated surface implants and 3 micro-treated surface implants [resorbable blast media surface (RBM), sandblast and acid-etched surface (SAE), anodized RBM surface] were used as experimental groups. Removal torque values of implants were measured respectively and the histological analyses were conducted on both 4weeks and 8weeks after implant surgery. The surfaces of removed implants after measuring removal torque values were observed by scanning electron microscopy (SEM) at 8 weeks. **RESULTS.** 1. Removal torque values of the nano-treated groups were lower than those of micro-treated groups. 2. Removal torque values were similar in the anodized RBM surface groups. 3. On the histological views, there was much of bone formation at 8 weeks, but there was no difference between 4 and 8 weeks, and between the types of implant surfaces as well. **CONCLUSION.** It is suggested that implant topography is more effective in removal torque test than surface chemistry. To get better clinical result, further studies should be fulfilled on the combined effect of surface topography and chemistry for the implant surface treatments. **KEYWORDS.** removal torque, implant, surfaces characteristics, dog, histology, SEM [J Adv Prosthodont 2009;1:75-84]

## INTRODUCTION

Osseointegration is the essential biological basis of the current dental implants.<sup>1</sup> Many researchers have found that the responses of cell and tissue to implant is affected not only by the chemical properties, but also the surface topography or roughness of the implant surfaces.<sup>2</sup> So, there were many efforts to modify titanium implant surface to achieve better tissue responses.

The implant surfaces characteristics most frequently described in the literature may be subdivided into implants with roughened surfaces by coated (titanium plasma spray, hydroxyapatite, etc), implants with roughened surfaces with the electrochemical modifications (anodic oxidation) of the commercially pure titanium implants, and implants with roughened surfaces without coated (sand-blasted, acid-etched etc). These surfaces were known to promote initial healing capacity by roughness.<sup>10</sup> The bone formation that occurs during osseointegration may show the osteoblast activities which are affected by the implant surfaces.<sup>13</sup> A number of *in vitro* and *in vivo* studies have been conducted to compare the effect of implant surfaces on the bone formation. Novaes and colleagues<sup>14</sup>

compared hydroxyapatite (HA), titanium plasma-sprayed (TPS), sandblasted, and machined implants. They found that in the relation to bone implant contact (BIC), the sandblasted surfaces were statistically superior to the turned surfaces and showed greater BIC than the HA and TPS surfaces after 90 days in place without loading. Human histologic findings demonstrated the improved BIC on rough surfaced implants compared to turned surfaced implants.<sup>15</sup> When the surface topography of an implant is altered, its surface chemistry is also altered. Cell behavior is not dependent on topography alone; surface topography and chemistry are inseparable. In a study investigating bone tissue reactions to various surface oxide properties, Sul<sup>16</sup> concluded that, either separately or altogether, surface chemistry and topography play important roles of bone responses to the implant surfaces. Recently, a number of studies about nano-treated surfaces of implants have been conducted. Oh *et al.* cited that<sup>28</sup> TiO<sub>2</sub> nanotube arrays and associated nanostructures could be useful as the well-adhered bioactive surface layers on Ti implant metals and alloys for orthopedic and dental applications. Karlsson *et al.*<sup>29</sup> suggested that the anodized nano-porous alumina membranes seem to provide better surface for osteoblastic cell growth, with cells

Corresponding author: Sang-Won Park

Department of Prosthodontics, School of Dentistry, Chonnam National University  
300 Yongbong-dong, Buk-ku, Kwangju, 500-757, Korea

Tel, +82 62 530 5842; e-mail, psw320@chonnam.ac.kr

Received January 28, 2009 / Last Revision February 25, 2009 / Accepted July 15, 2009,

© 2009 The Korean Academy of Prosthodontics

This is an Open Access article distributed under the terms of the Creative Commons Attribution Non-Commercial License (<http://creativecommons.org/licenses/by-nc/3.0>) which permits unrestricted non-commercial use, distribution, and reproduction in any medium, provided the original work is properly cited.

rapidly spreading, flattening and adhering firmly to the surfaces of the materials. The purpose of this study was to measure the removal torque values and analyze the histological characteristics after placement of various surface-treated implants on femurs of dogs.

## MATERIAL AND METHODS

### Surface characteristics of the fixture

Eight different types of dental implants were designed for present study (Table I and Fig. 1).

Implants in machined surface group were produced by a Company (ExFeel®, MEGAGEN, Kyungsan, Korea).

Implants surfaces in nano-treated surface groups were treated by sputtering method in laboratory.

For group 2 and 4, the sputtering parameters were as follows: 300 W,  $(1.0 - 1.2) \times 10^2$  torr, for 3 h. Group 4 is heat-treated at 600 °C for 1 hour after deposition.

For group 3 and 5, the sputtering parameters were as follows: dental implants were coated by sputter-coated using a CMS-18 radiofrequency magnetron sputtering system (Kurt J. Lesker Company, Clairton, PA, USA). The machine was operated at 300 W,  $1.0 - 1.2 \times 10^2$  torr, for 7 h. Pins were rotated 120 degree between each of three coated periods to cover the entire 360° surface of the specimens. CaP pins were subjected to a post coated heat treatment of 600 °C for 1 h to achieve 60% crystallinity.

Implants surfaces in micro-treated surface groups were produced by a company (ExFeel®, MEGAGEN, Kyungsan, Korea)

For group 6, 7 and 8, sanding conditions are as follows:

**Table I.** Surface characteristics

Group		Surface characteristics	n
Control	1	Machined surface	8
Nano-treated	2	20 nm TiO <sub>2</sub> coated surface	8
	3	CaP coated surface	8
Micro-treated	4	Heat treated 80 nm TiO <sub>2</sub> coated surface	8
	5	Heat treated CaP coated surface	8
	6	Resorbable blast media surface	8
	7	Sandblast and acid-etched surface	8
	8	Anodized RBM surface	8

MCD apatitic abrasive (Hi-Med Co, NJ, USA) was used under about 150 mesh, 5 atm condition.

For group 7, the etching conditions were as follows: in etching solution (HCl:H<sub>2</sub>SO<sub>4</sub> = 4 : 1) group 7 was treated at 80 °C for 5 minute after blasting.

For group 8, anodizing conditions were as follows: in an electrolytic solution for dental implants calcium and phosphate were dissolved in water. The electrolytic voltage was set in the range of 170 - 320V and the current density was 30 mA/cm<sup>2</sup>.

Total 64 implants, 3.75 mm diameter × 10 mm length, were installed by self-tapping.

### Experimental animals and anesthesia

Four healthy adult dogs, with body weights ranging from 15 to 20 kg were used in this study. The dogs were anesthetized with the combinations of Ketamine (5 mg/kg, Yu-han, Gunpo, Korea) and Rompun (0.3 mg/kg, Bayer Korea, Ansan, Korea) intramuscularly.

### Surgical procedures and implant placement

Both hind legs were prepared in the standard sterile fashions. The flat surface on the lateral aspect of the proximal femur was selected for the implant placement. The skin incision was performed to expose the whole lateral aspect of femur, muscles were dissected to allow elevation of the periosteum and then implant sites were prepared. All implants were 3.75 mm in diameter, which were larger than the final drill sizes, which were 3.3 mm in diameter. Eight implants sites were drilled on each leg using specially designed acrylic stent (Fig. 2).

### Postsurgical treatment

The surgical site was closed in layers with resorbable suture materials (SURGIFIT, AILEE Co Ltd, Korea). All animals received 50 injection of 0.15 ml/kg Baytril® 50 (Bielkorea, Seoul, South Korea) for 7 days and 0.1 ml/kg Pirin® (Green Cross Veterinary Products Co, Seoul, Korea) for 2 days intramuscularly.

### Animals sacrifice

Two animals were sacrificed at 4 weeks and another two at 8 weeks after surgery by the injection of overdose of thiopental sodium (T6023, Sigma, MO, USA).



**Fig. 1.** Eight fixtures with differently treated implant surface. From left; a. Machined surface, b. 20 nm TiO<sub>2</sub> coated surface, c. CaP coated surface, d. Heat treated 80 nm TiO<sub>2</sub> coated surface, e. Heat treated CaP coated surface, f. Resorbable blast media (RBM) surface, g. Sandblast and acid-etched (SAE) surface, h. Anodized RBM surface.

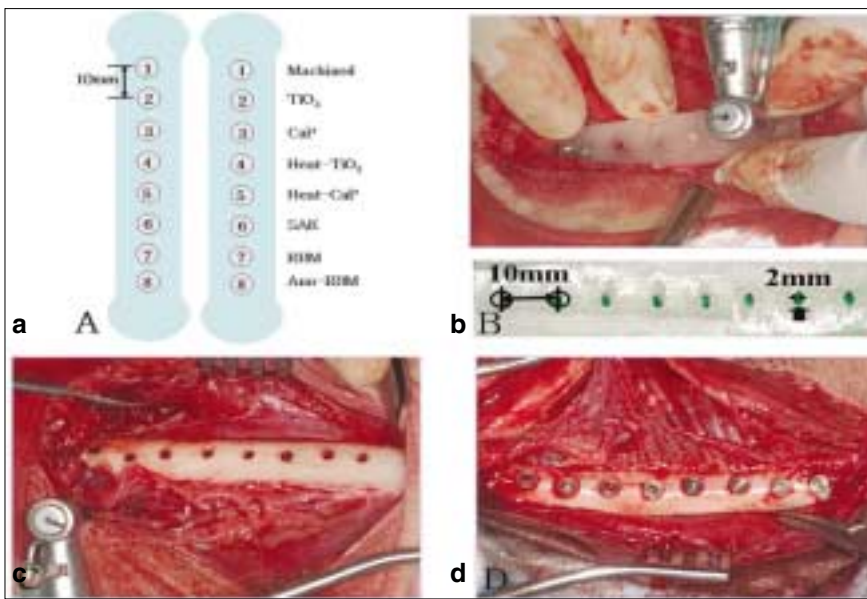


Fig. 2 a. Implant placement diagram. b. Acrylic stent which has guide holes 10 mm apart. c. Implants were placed in order. d. Mounts were removed.




Fig. 3. a. The jig was especially designed for removal torque measurement. The upper part of the metal jig was able to move from the middle into the space where the arrow was directed and the lower part can move back and forward. This kind of movement was necessary to place the hole of the upper part of the jig that can position on the right surface of the implant fixtures. b. Removal torque measurement device (MGT12, ELECTROMATIC Equipment, NY, USA). c. Connect the fixture mount with implants. d. Mount holder was attached with the measured appliance and measured the removal torque.

**Removal torque values measurement**

The implants and adjacent tissues were removed en bloc. Removal torque values were measured with a torque measurement device (MGT12, ELECTROMATIC Equipment, NY, USA) (Fig. 3). When the ruptures between bones and implants occurred, the peak force values fell quickly.

**Scanning electron microscopy (SEM)**

After the removal torque test at 8 weeks, the implants were fixed in the neutral buffered formalin. After dehydration in a graded series of alcohol, the implants were dried and mounted on metallic stubs using double side tapes. All samples were placed in the vacuum chamber of the SEM. Thereafter, the implant surfaces were observed by SEM (S-4700, Hitachi, Tokyo, Japan).

**Preparation of specimens and the histological analyses**

The implants, after measuring removal torque value, were removed from bones in the 8-th week experimental group to see the SEM of removed implant surfaces, but the implants after measuring removal torque value were replaced with the original site to see better bone implant relationships in the 4-th week experiment group. The implants and surrounding bones were fixed in the neutral buffered formalin, dehydrated with ascending concentrations of ethanol for 24 h at each stage. Following transitional acetone immersion, the samples were immersed in 100% polymethylmethacrylate monomer for 24 h, followed by immersion in a 1 : 1 ratio of polymethylmethacrylate to methylmethacrylate monomer for 24 h. The samples were placed in the embedding molds containing polymethylmethacrylate resin for 24 h. Thereafter, the samples were

transferred to fresh methylmethacrylate and bench top-cured at room temperature for 10 days. Once the plastic was hardened to the touch, the samples were placed into a 37°C oven for the final curing for 7 to 10 days. The samples were serial sectioned with a Buehler Isomet saw (Buehler, Lake Bluff, IL, USA) using diamond wafering blades at the initial thicknesses of 150 μm. The sections were hand-ground with diamond disks to the final thickness of approximately 30 to 50 μm for subsequent analyses. In this manner, 3 to 4 sections were obtained buccolingually to the implants. The sections were stained with hematoxylin and eosin. Photomicrographs for histologic analyses were taken using a Leitz Orthoplan microscope (Eclipse 80i, Nikon, Japan) at various magnifications.

**Statistics analyses**

The differences of removal torque values were analyzed by two-way ANOVA and for post hoc comparison Duncan's test was executed. All calculations were made using SPSS Version 12 for Windows.

**RESULTS**

**Removal torque values**

The removal torque values, measured after a 4-week and 8-week healing period, were summarized in Table II. The mean values of the removal torque and diagram were found (Fig. 4). The removal torque value of one implant (heat treated CaP coated surface) of a dog sacrificed at 8 week was not measured because the femur was fractured and the implant at frac-

tured site failed to be osseointegrated (Fig. 5).

**Scanning electron microscopy (SEM)**

The surfaces of removed implants in nano-treated groups showed relatively clean surfaces with a few bone tissues and the surfaces of removed implants in micro-treated groups showed rough surface with much bone tissue or organic residues (Fig. 6).

**Histological analyses**

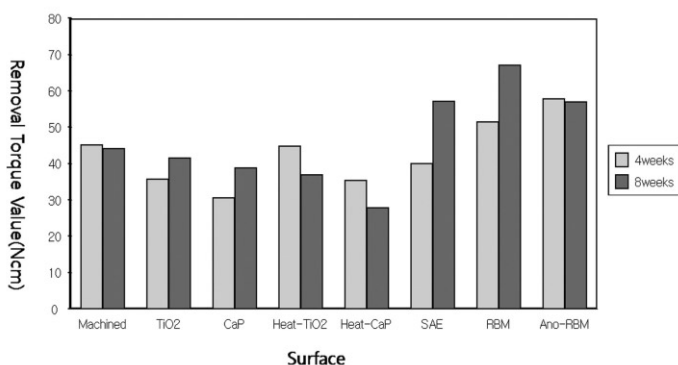
Every implant was osseointegrated well except one implant that was placed at the fracture site. There was much of bone formation at 8-weeks groups, and all implants showed good healing. Bone tissue was distinctively observed and showed the intimate contact with implants in the cortex area. In medulla area, much endosteal bone formation was observed on adjacent area to cortex and had thin trabecular patterns. There was no difference between 4 weeks (Fig. 7) and 8 weeks (Fig. 8), and between the types of implant surfaces as well.

**DISCUSSION**

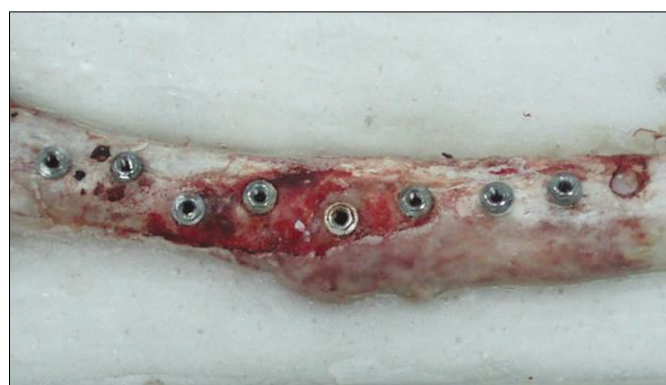Many studies showed that surface roughness has a positive influence on the resistance to shear and tensile forces.<sup>18-19</sup> However, the degree of surface roughness may not be the only aspect of surface topography that effects osseointegration. The intimacy of bone contact with the implant surface may be important as may the ionic charge, surface energy and surface tension or other still undefined properties of the surface.

**Table II.** Removal torque values (Ncm) data after 4-week of healing time

		Machined	TiO <sub>2</sub>	CaP	Heat-TiO <sub>2</sub>	Heat-CaP	SAE	RBM	Ano-RBM
1 <sup>st</sup>	left	41.4	24.2	25.7	40.7	31.5	40.7	58.1	43.5
dog	right	53.7	34.7	28.6	34.9	36.4	35.6	56.8	65.0
2 <sup>nd</sup>	left	46.5	59.1	38.5	72.8	54.6	37.9	32.8	50.6
dog	right	39.2	25.6	29.6	31.3	19.3	46.3	58.2	72.7
Mean		45.2	35.9	35.9	44.9	35.5	40.1	51.5	58.0




**Fig. 4.** A diagram of removal torque value at 4-th and 8-th week. It showed the mean values of removal torque value between 4 weeks and 8 weeks and there was no statistic significance ( $P > .05$ ).

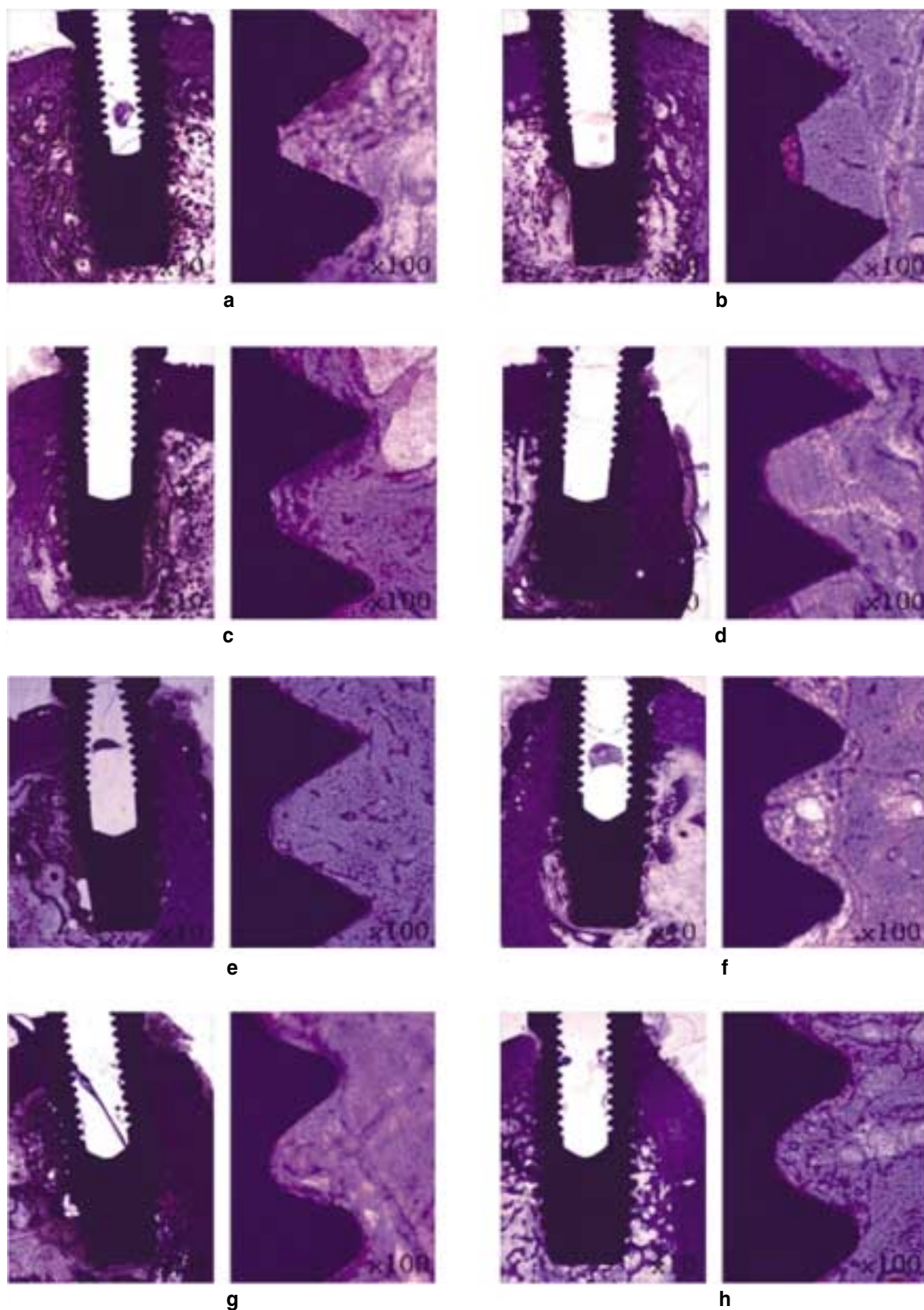


**Fig. 5.** A fracture site of femur. one femur of a dog sacrificed at 8 week was fractured at midline and one implant at fractured site failed to be osseointegrated.

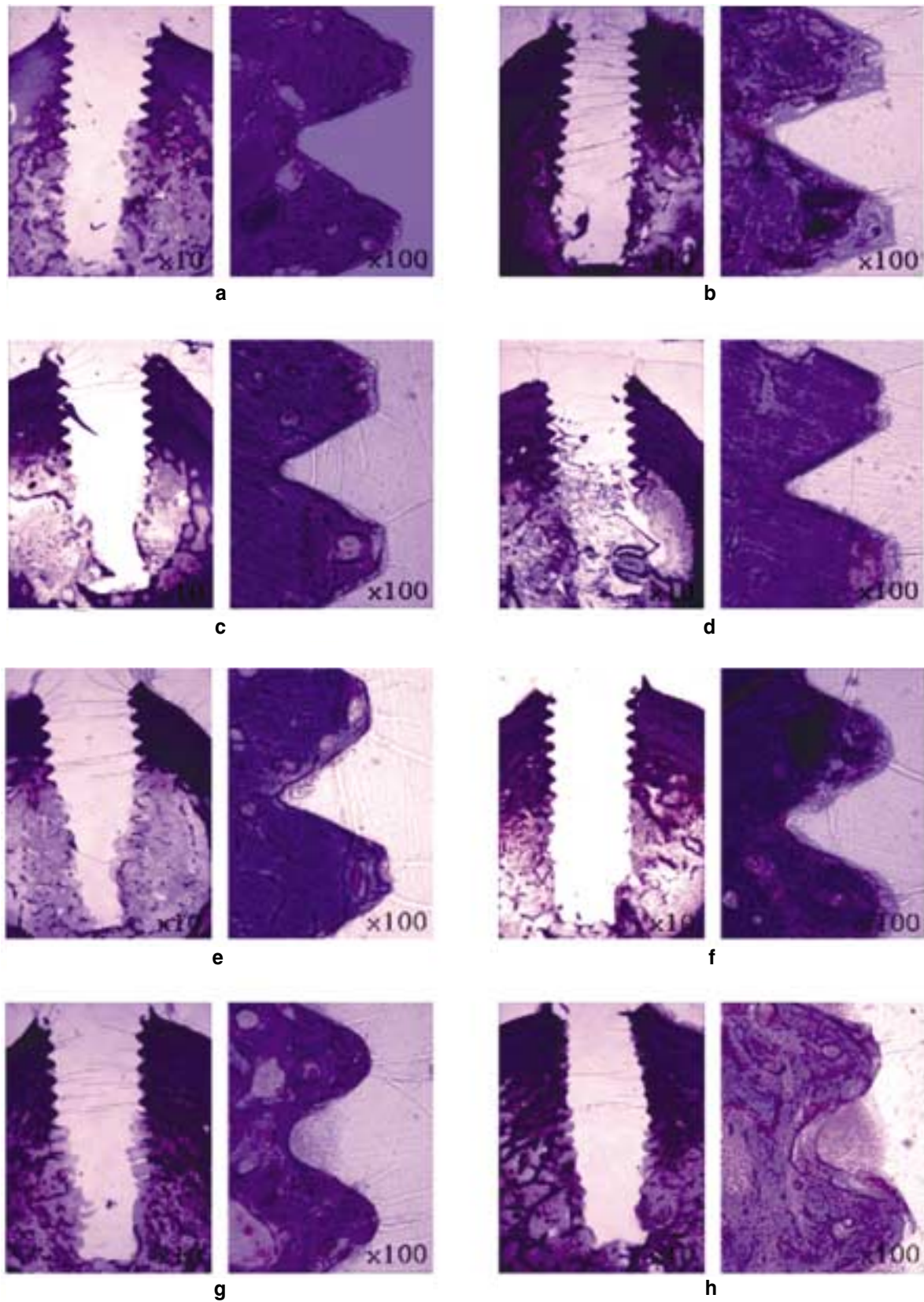




**Fig. 6.** Scanning electron microscopy of removed implant surfaces. a. Machined surface. b. 20 nm TiO<sub>2</sub> coated surface. c. CaP coated surface. d. Heat treated 80 nm TiO<sub>2</sub> coated surface. e. Heat treated CaP coated surface. f. Sandblast and acid-etched (SAE) surface. g. Resorbable blast media (RBM) surface. h. Anodized RBM surface.



**Fig. 7.** The histological section in the buccolingual direction at 4 weeks. a. Machined surface, b. 20 nm TiO<sub>2</sub> coated surface, c. CaP coated surface, d. Heat-TiO<sub>2</sub> coated surface, e. Heat CaP coated surface, f. SAE, g. RBM, h. Anodized RBM. All implants osseointegrated well. Bone quality of the original sites was different dependent on the installed sites of implants.



**Fig. 8.** The histological sections in the buccolingual direction at 8 weeks. a. Machined surface, b. 20 nm TiO<sub>2</sub> coated surface, c. CaP coated surface, d. Heat-TiO<sub>2</sub> coated surface, e. Heat CaP coated surface, f. SAE, g. RBM, h. Anodized RBM. All implants were removed after measuring the removal torque values.



According to Webster *et al.*<sup>19,20</sup> an introduction of nanostructure significantly improves osteoblast adhesion. Adhesion of cells such as osteoblast is a crucial prerequisite to subsequent cell functions such as the synthesis of extracellular matrix proteins, and the formation of mineral deposits. New bone at first forms on the implant surfaces in the process of contact osteogenesis, and only then a combination of the recruitment and migration of osteogenic cells and bone formation by those cells on the implant surface occurs.

The dog was chosen as the animal model for this pilot study, as the femur of this animal has the uniform bone quality, because the purpose of this study was to compare the values according to the implant surfaces. Under the assume of the uniformity of the bone quality (cortical-cancellous ratio), the experiments were done. The bone quality has similar pattern in the radiographs, so the problem of the places of implants was excepted. However, the implants were not placed at the mid-sagittal of the femur and the cortical-cancellous ratio was not constantly maintained. A rough estimate of comparative healing rates between dogs and humans would suggest that the events of wound healing and bone remodeling happened approximately 1.5 times sooner in dogs than would occur in the human, 4 weeks for dog means 6 weeks for human.

The process of osseointegration is affected by many factors, including surgical techniques and the conditions of the implant bed.<sup>23</sup> Clinical observations have also indicated that the final healing time is affected by individual differences and operation conditions.<sup>24</sup> In this study, same clinician installed implants and the implants were planted always the same place with the same sequences. All implants except one that installed at the fracture site of femur healed well. It means that the suitable implant number according to the different bone conditions should be considered avoiding the fracture of bones under the different loading circumstances.

A greater removal force can be generally interpreted as an increase in bone healing around the implants and improvement in osseointegration. In this study, removal torque values of nano-treated group were lower than those of micro-treated group at both 4 weeks and 8 weeks. This result implies that micro-treated surface have better conditions to satisfy the osseointegration than nano-treated surface and surface roughness is more important than surface composition for the resistance of removal torque. In RBM surface and SAE surface group, removal torque value was increased at 8 weeks compared to at 4 weeks. This means that osseointegration is influenced more by the bone maturity than the bone strength. But in the anodized RBM surface group which was additionally treated with anodizing oxidation on sandblasted micro-roughness surface, the removal torque values at 4 weeks & 8 weeks were similar. It seems that when anodized treatment was added to micro-roughness, osseointegration was done at the early stage.

Berglundh and co-workers<sup>21</sup> reported, in a study *in vivo*, at 8 and 12 weeks, there were the marked signs of remodeling within the wound chamber. It means that the implants have no mechanical and functional problems on the loading after 4 weeks. In this study, it was suggested that there was no mechanical and functional problems, if the implants had been loaded after 4 weeks. In the histologic findings of this study, most of all implants showed the bone-to-implant contact along the full length of the implant and to a level coronal to the first thread at 4 and 8 week. There was no significant difference between 4 weeks and 8 weeks, and between the types of implant surfaces as well.

Factors such as material biocompatibility, implant design and surface, surgical techniques, host bed, and the loading conditions may all influence implant osseointegration.<sup>25</sup> Consequently, modifications in implant body design and implant surfaces have been suggested to increase the success in poor quality bone by hypothetically, gaining better anchorage and providing more surface area of the load to decrease stress to the softer bone types.<sup>26</sup> Salata and coworkers<sup>27</sup> have suggested that faster development of implant stability for oxidized implants than turned components when placed in bone defects. Bone formation towards the rough surfaced implant is facilitated by a more stable connection between bone matrix and the implant surface, which can be explained by the degree of protein adsorption on the anodic-oxidized implants. Glauser *et al.*<sup>26</sup> concluded that the applied immediate loading protocols in the combination with a slightly tapered implant and a modified implant surface texture was shown to be a successful treatment alternative even in regions exhibiting soft bones. The results from the study by Olsson *et al.*<sup>27</sup> indicated that early loading can be applied to the cross-arch dental bridges supported by six to eight oxidized implants in the maxilla. From this study, it seems that the surface composition may be least effective factor in clinical loading conditions.

In the SEM view of removed implants at 8 weeks, the surfaces of removed implants in nano-treated groups showed relatively clean surfaces with a little bone tissue but the surfaces of removed implants in micro-treated groups showed rough surface with much bone tissue or organic residues. It seems that micro-roughness surface would be more resistant to removal torque than nano-surface, because mechanical locking effect could be achieved on rotational force applied to implants.

This study has showed no statistical significances between the surfaces of implants. This meant that each surface of the implants had a few number of it and the differences between the dogs were so huge that the measurements of the standard deviation gave large numbers. Between the 4 weeks and 8 weeks, it had no statistical significance because of the initial formation of osseointegration at the early stage.

The tissue responses may not depend on only one specific surface property but rather on a number of different alterations.



However, it is not fully understood whether these properties influence the bone tissue response separately or synergistically. In this study the experimental condition may not always be extrapolated the clinical situations. This may be due to differences in bone anatomical, physiological, and unloaded conditions.

In this study, micro-treated groups have showed higher ability of removal than nano-treated groups and these revealed different results than the review of Webster. In addition, both nano- and micro-treated surface implants showed no statistical significance. However, between the 4 and 8 weeks, the results showed no differences and it meant initial osseointegration had occurred at the early stage.

From this experiment, we can suggest that the nano-treated surface that newly start to be investigated need to be studied in combination with micro-treated surfaces for better clinical results rather than it is studied by itself.

## CONCLUSION

From this study, following results were obtained: Removal torque values of the nano-treated groups were lower than those of micro-treated groups at both 4 week and 8 week. There were no statistically significant difference between the groups, the machined group and nano-treated groups with smooth surfaces relatively had similar removal torque values at both 4 weeks and 8 weeks, but micro-treated groups showed higher removal torque values at 8 weeks than at 4 weeks. Removal torque values at both 4 weeks and 8 weeks were similar in the anodized RBM surface groups and this suggested that osseointegration was done at the early stage compared to RBM surface and SAE surface groups. On the histological views, there was much of bone formation at 8 weeks, but there was no difference between 4 and 8 weeks, and between the types of implant surfaces as well. On the SEM views, the surfaces of removed implants in nano-treated groups showed relatively clean surfaces with few bone tissue while the surfaces of removed micro-treated implants showed rough surface with much bone tissues.

From this experiment, it is suggested that implant topography is more effective in removal torque test than surface chemistry. To get better clinical result, further studies should be fulfilled on the combined effect of surface topography and chemistry for the implant surface treatments.

## REFERENCES

- Li DH, Liu BL, Zou JC, Xu KW. Improvement of osseointegration of titanium dental implants by a modified sandblasting surface treatment: an *in vivo* interfacial biomechanics study. *Implant Dent* 1999;8:289-94.
- Buser D, Schenk RK, Steinemann S, Fiorellini JP, Fox CH, Stich H. Influence of surface characteristics on bone integration of titanium implants. A histomorphometric study in miniature pigs. *J Biomed Mater Res* 1991;25:889-902.
- Bowers KT, Keller JC, Randolph BA, Wick DG, Michaels CM. Optimization of surface micromorphology for enhanced osteoblast responses *in vitro*. *Int J Oral Maxillofac Implants* 1992;7:302-10.
- Brunette DM. The effects of implant surface topography on the behavior of cells. *Int J Oral Maxillofac Implants* 1988;3:231-46.
- Mustafa K, Silva Lopez B, Hultenby K, Wennerberg A, Arvidson K. Attachment and proliferation of human oral fibroblasts to titanium surfaces blasted with TiO<sub>2</sub> particles. A scanning electron microscopic and histomorphometric analysis. *Clin Oral Implants Res* 1998;9:195-207.
- Johansson C, Albrektsson T. Integration of screw implants in the rabbit: a 1-year follow-up of removal torque of titanium implants. *Int J Oral Maxillofac Implants* 1987;2:69-75.
- Han CH, Johansson CB, Wennerberg A, Albrektsson T. Quantitative and qualitative investigations of surface enlarged titanium and titanium alloy implants. *Clin Oral Implants Res* 1998;9:1-10.
- Wennerberg A, Albrektsson T, Johansson C, Andersson B. Experimental study of turned and grit-blasted screw-shaped implants with special emphasis on effects of blasting material and surface topography. *Biomaterials* 1996;17:15-22.
- Ericsson I, Johansson CB, Bystedt H, Norton MR. A histomorphometric evaluation of bone-to-implant contact on machine-prepared and roughened titanium dental implants. A pilot study in the dog. *Clin Oral Implants Res* 1994;5:202-6.
- Larsson C, Thomsen P, Aronsson BO, Rodahl M, Lausmaa J, Kasemo B, Ericson LE. Bone response to surface-modified titanium implants: studies on the early tissue response to machined and electropolished implants with different oxide thicknesses. *Biomaterials* 1996;17:605-16.
- Sul YT, Johansson CB, Jeong Y, Wennerberg A, Albrektsson T. Resonance frequency and removal torque analysis of implants with turned and anodized surface oxides. *Clin Oral Implants Res* 2002;13:252-9.
- Letić-Gavrilović A, Scandurra R, Abe K. Genetic potential of interfacial-guided osteogenesis in implant devices. *Dent Mater J* 2000;19:99-132.
- Novaes AB Jr, Souza SL, de Oliveira PT, Souza AM. Histomorphometric analysis of the bone-implant contact obtained with 4 different implant surface treatments placed side by side in the dog mandible. *Int J Oral Maxillofac Implants* 2002;17:377-83.
- Ivanoff CJ, Hallgren C, Widmark G, Sennerby L, Wennerberg A. Histologic evaluation of the bone integration of TiO<sub>2</sub> blasted and turned titanium microimplants in humans. *Clin Oral Implants Res* 2001;12:128-34.
- Ivanoff CJ, Widmark G, Johansson C, Wennerberg A. Histologic evaluation of bone response to oxidized and turned titanium micro-implants in human jawbone. *Int J Oral Maxillofac Implants* 2003;18:341-8.
- Sul YT. The significance of the surface properties of oxidized titanium to the bone response: special emphasis on potential biochemical bonding of oxidized titanium implant. *Biomaterials* 2003;24:3893-907.
- Thomas KA, Kay JF, Cook SD, Jarcho M. The effect of surface macrotexture and hydroxylapatite coating on the mechanical strengths and histologic profiles of titanium implant materials. *J Biomed Mater Res* 1987;21:1395-414.
- Carlsson L, Röstlund T, Albrektsson B, Albrektsson T. Removal torques for polished and rough titanium implants. *Int J Oral Maxillofac Implants* 1988;3:21-4.
- Webster TJ, Ergun C, Doremus RH, Siegel RW, Bizios R. Enhanced functions of osteoblasts on nanophase ceramics. *Biomaterials* 2000;21:1803-10.
- Webster TJ, Schadler LS, Siegel RW, Bizios R. Mechanisms of enhanced osteoblast adhesion on nanophase alumina involve vitronectin. *Tissue Eng* 2001;7:291-301.
- Berglundh T, Abrahamsson I, Lang NP, Lindhe J. De novo alve-

- olar bone formation adjacent to endosseous implants. *Clin Oral Implants Res* 2003;14:251-62.
22. Ericsson I, Johansson CB, Bystedt H, Norton MR. A histomorphometric evaluation of bone-to-implant contact on machine-prepared and roughened titanium dental implants. A pilot study in the dog. *Clin Oral Implants Res* 1994;5:202-6.
  23. Schatzker J, Horne JG, Sumner-Smith G. The effect of movement on the holding power of screws in bone. *Clin Orthop Relat Res* 1975;111:257-62.
  24. Albrektsson T, Lekholm U. Osseointegration: current state of the art. *Dent Clin North Am* 1989;33:537-54.
  25. Misch CE. Density of bone: effect on treatment plans, surgical approach, healing, and progressive boen loading. *Int J Oral Implantol* 1990;6:23-31.
  26. Glauser R, Lundgren AK, Gottlow J, Sennerby L, Portmann M, Ruhstaller P, Hämmerle CH. Immediate occlusal loading of Brånemark TiUnite implants placed predominantly in soft bone: 1-year results of a prospective clinical study. *Clin Implant Dent Relat Res* 2003;5:47-56.
  27. Olsson M, Urde G, Andersen JB, Sennerby L. Early loading of maxillary fixed cross-arch dental prostheses supported by six or eight oxidized titanium implants: results after 1 year of loading, case series. *Clin Implant Dent Relat Res* 2003;5:81-7.
  28. Oh SH, Finönes RR, Daraio C, Chen LH, Jin S. Growth of nano-scale hydroxyapatite using chemically treated titanium oxide nanotubes. *Biomaterials* 2005;26:4938-43.
  29. Karlsson M, Pålsgård E, Wilshaw PR, Di Silvio L. Initial *in vitro* interaction of osteoblasts with nano-porous alumina. *Biomaterials* 2003;24:3039-46.